

Basic Shoulder Arthroscopy: Lateral Decubitus Patient Positioning



Alexander H. Jinnah, M.D., Sandeep Mannava, M.D., Ph.D., Johannes F. Plate, M.D., Ph.D.,
Austin V. Stone, M.D., Ph.D., and Michael T. Freehill, M.D.

Abstract: Shoulder arthroscopy offers a minimally invasive surgical approach to treat a variety of shoulder pathologies. The patient can be positioned in either the lateral decubitus or the beach chair position. This note and accompanying video describe the operating room setup for shoulder arthroscopy in the lateral decubitus position, including positioning of the arms, head, and sterile preparation and draping. Appropriate lateral decubitus positioning for shoulder arthroscopy with careful attention to detail will promote ease of surgical intervention and minimize complications.

Shoulder arthroscopy is a common orthopaedic procedure.¹⁻³ Its popularity can be attributed to the evolving technology, instrumentation, and expanding surgical indications for arthroscopic shoulder procedures.³ The evolution of shoulder arthroscopy has directly led to the expansion of surgical intervention from a purely diagnostic tool to the ability to perform minimally invasive, but complicated repair and reconstructive procedures.

Two patient positioning options are available to the surgeon performing the procedure: the beach chair or the lateral decubitus position. The beach chair position allows easier conversion to an open procedure and provides a more upright, anatomic position; however, there are potential mechanical blocks from the operating table and an increased risk of cerebral hypoperfusion under general anesthesia associated with this

position.⁴ Conversely, the lateral decubitus position provides a nonanatomical orientation, but uses traction, thus increasing the space in the glenohumeral joint and subacromial space, as well as better visualization and improved surgical treatment of labral tears.⁴ The decision as to which position will be used is based on surgeon preference, because neither position has shown superiority to the other.^{1,4-7}

This note and [Video 1](#) review the operating room setup for shoulder arthroscopy and lateral decubitus patient positioning. Furthermore, the potential pearls and pitfalls for the proper setup in the lateral decubitus position will be outlined ([Table 1](#)). Proper positioning for this procedure will minimize complications and facilitate the ease of surgical intervention.

Surgical Technique

Application of Anesthesia

The patient is brought to the operating room after necessary preoperative safety protocols, such as marking of the operative extremity. The anesthesia team will induce general anesthesia and may use an interscalene nerve block for analgesia during the perioperative and early postoperative period for shoulder arthroscopy. The interscalene nerve block is performed in the preoperative holding area at our institution to decrease time in the operating room.

The anesthesia staff preserves normothermia during the procedure with the infusion of warmed intravenous saline solution and an inflatable warming blanket (3M Bair Hugger Intraoperative Blankets, St. Paul, MN).⁸

From the Department of Orthopaedic Surgery, Wake Forest School of Medicine, Winston-Salem, North Carolina, U.S.A.

The authors report the following potential conflicts of interest or sources of funding: M.T.F. receives support from Smith & Nephew, DJO, and DePuy Mitek. S.M. receives support from a Wake Forest Innovations Spark Award Research Grant (institutional research funding for development of a tensioning device for use during rotator cuff tendon repair and similar tendon repair surgery) and a patent (Patent No. 08926626) issued to him by the United States Patent and Trademark Office.

Received February 15, 2016; accepted May 25, 2016.

Address correspondence to Michael T. Freehill, M.D., Department of Orthopaedic Surgery, Wake Forest School of Medicine, Winston-Salem, NC 27157, U.S.A. E-mail: freehill@wakehealth.edu

© 2016 by the Arthroscopy Association of North America. Open access

under CC BY-NC-ND license.

2212-6287/16145

<http://dx.doi.org/10.1016/j.eats.2016.05.010>

Table 1. Potential Pearls and Pitfalls for Lateral Decubitus Positioning for Shoulder Arthroscopy

Pearls	Pitfalls
<ul style="list-style-type: none">• Safety timeouts before surgical positioning, draping, and incision as per institutional protocol• Ensure that appropriate equipment for positioning is available before the surgical procedure• Position patients in the same way each case to avoid any variability between cases• Confirm that the genitals, areolae, and bony prominences are not under undue pressure from the beanbag before preparation and draping• Verify that padding is over the lateral aspect of the knee to assure protection of the common peroneal nerve and bony prominences of the leg• Use 10-12 lb of traction for women and 12-15 lb of traction for men	<ul style="list-style-type: none">• A known risk is traction neuropraxia• Deep venous thrombosis (proper application of sequential compression devices may be used to prevent deep venous thrombosis)• Compression neuropraxia may occur from inadequate padding of nerves• Decubiti formation is possible from inadequate padding of bony prominences

Operating Room Setup

The operative setup is shown in [Figure 1](#). The surgeon, surgical assistant, and surgical technologist (scrub), along with the primary instrument table and Mayo stand, are positioned posterior to the patient while lying on their nonoperative side. The fluid management system, arthroscopic monitor, and operative devices such as radiofrequency and arthroscopic shaver stations are positioned anterior or in front of the patient on their nonoperative side. The monitors and equipment should be placed for maximum visibility for the surgeon during the operative procedure, while permitting access by the circulating nurse, without compromising the sterile field.

Patient Positioning

The patient is placed in the supine position on the operating table and endotracheal anesthesia is commenced. Anesthesia has performed intravenous access on the nonoperative extremity and lubricates the eyes to prevent corneal abrasion. Sequential compression devices (Kendall SCD Express Sleeves, Knee Length, Covidien Ltd., Mansfield, MA) are placed on the lower extremities for deep venous thrombosis prophylaxis. The surgical assistant and the surgeon then turn the patient onto the nonoperative side. During this step it is important to be careful to not compress the nonoperative arm. Towels are placed under the head to prevent cervical strain, and a padded cylinder axillary

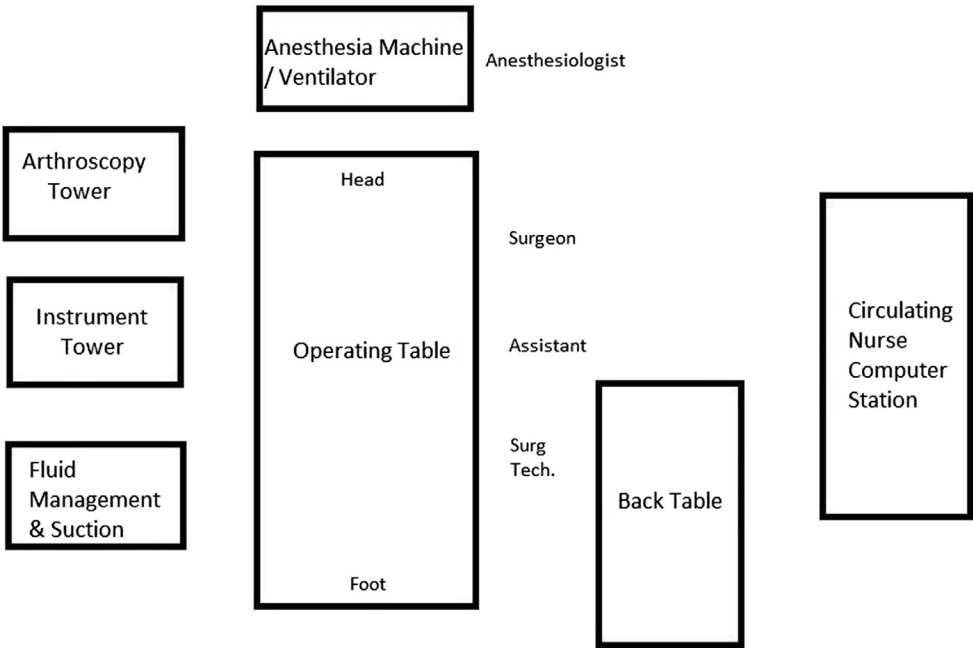
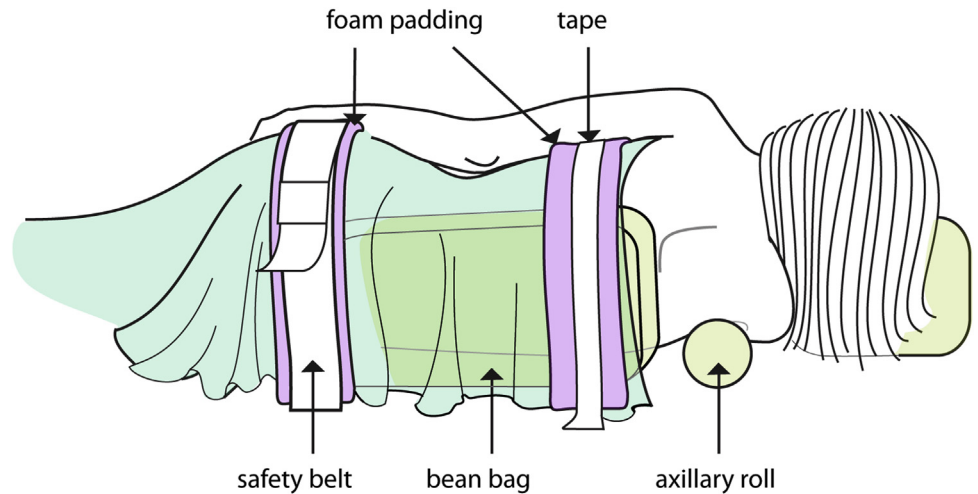


Fig 1. Operative room setup for left shoulder arthroscopy. The locations of different instruments and equipment in the operating theater are shown. The surgeon, surgical assistant, and surgical technologist (scrub) are positioned on the operative side or posterior to the thorax of the patient. The arthroscopic monitor, fluid management system, and operative device units are positioned anterior or to the chest side of the patient.

Layout of Operating Theater for Left Shoulder Arthroscopy

Fig 2. The patient is positioned laterally by using a vacuum-sealed beanbag; stability is then assured with a safety belt and foam padding across the waist and further secured by foam padding and heavy tape across the torso and the legs. An axillary roll is then placed beneath the axilla of the nonoperative extremity to protect the neurovascular structures during the procedure.



roll is placed beneath the axilla on the nonaffected extremity facing down (Fig 2). A space is left to avoid direct compression into the axilla. A beanbag (Olympic Vac-Pac, Natus Medical Incorporated, Seattle, WA), which had been placed under the patient to maintain stability in the lateral position intraoperatively, is maintained under a vacuum suction to ensure deflation (firmness) and stabilization throughout the procedure. The genitals, areolas, and bony prominences should be checked to avoid undue pressure from the beanbag. The contralateral arm is placed on an arm board (Pivoting Arm Board with 2" Tempur-Pedic Medical Pressure Equalization Pad, Mizuho OSI, Union City, CA) and held in place with a padded strap (Arthrex, Naples, FL) to keep the limb out of the operative field during the procedure. A seat belt is then placed over the lateral pelvis to secure the patient to the operative table during

the operation. Foam padding is placed between the skin of the patient and the seat belt to prevent irritation of the skin. A pillow is placed between the lower extremities to prevent excess pressure of the bony prominences, and then a piece of foam padding is taped over the top of the lower limb ipsilateral of the operative side (Fig 3). The down leg is slightly bent and then the upper leg is more straight. The common peroneal nerve is protected by padding the lateral aspect of the knee. Foam padding is also placed between the "down leg" and the beanbag to reduce pressure on the bony prominences of the leg during surgery and protect the common peroneal nerve. Additional foam padding can be placed over the patient's upper and mid-torso for added stability and secured by heavy cloth tape. The lateral head is then covered by a piece of foam padding to protect the patient's face and secured with plastic tape.

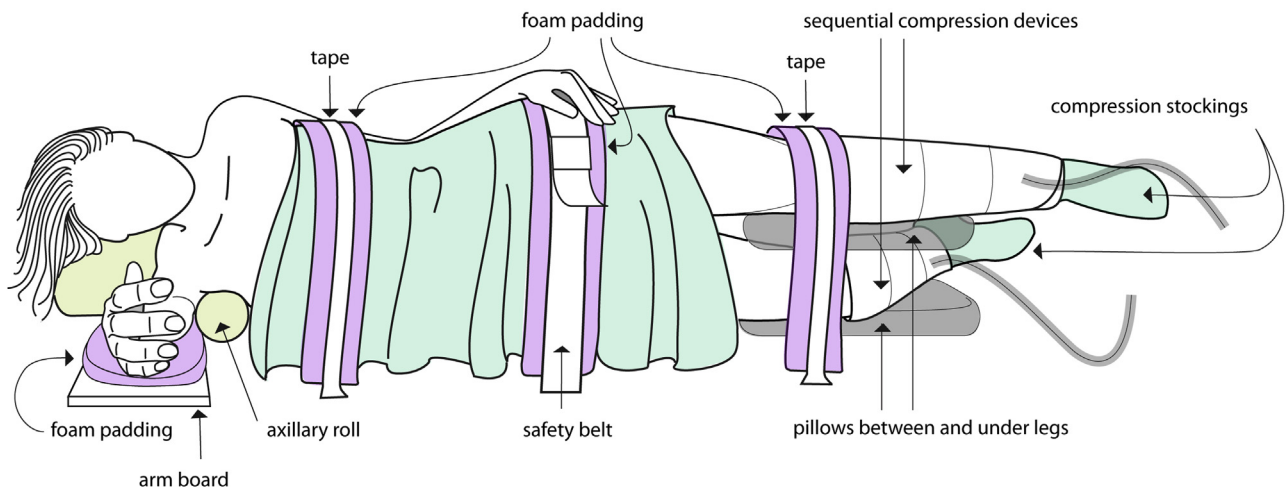


Fig 3. A pillow is placed between the lower extremities (down leg slightly bent and upper leg straight) to prevent excess pressure of the bony prominences and then a piece of foam padding is taped over the top of the lower limb ipsilateral of the operative side. The common peroneal nerve is protected by padding the lateral aspect of the knee.

The shoulder is now examined under anesthesia, as can be seen in [Video 1](#). A clear plastic U-Drape (U-Drape-3M Steri-Drape 1015, 3M Health Care, St. Paul, MN) is then placed across the axilla and up the chest and back, followed by a second clear U-Drape (U-Drape-3M Steri-Drape 1015, 3M Health Care) across the neck and down the chest and back to isolate the surgical field. Care must be taken to not drape out any of the needed surgical field. Furthermore, the sticky U-draperes must be placed on without tension to avoid peeling off the patient intraoperatively.

The operative extremity must now be placed in traction to expose the joint space during the procedure. We attach an “A-frame” pulley system (Shoulder Traction Holder, supplied with S-hook, Smith and Nephew, Andover, MA) to the end of the bed and adjust the frame so the arm will be fully extended at the elbow when attached, with the traction force pulling up and away from the body. A Skin-Trac (Zimmer, Warsaw, IN) is placed through the end of the pulley system and then attached to the forearm, with care being taken not to compress the hand to avoid any neurovascular complications. The operative extremity is then wrapped in an ACE wrap elastic bandage (3M Health Care), and traction is placed on the other end of the pulley. The amount of weight used for traction is based on surgeon preference, and is patient specific (the senior author [M.T.F.] prefers 10-12 lb for women and 12-15 lb for men). Once the patient is properly positioned ([Fig 4](#)), a

surgical preparation timeout is performed to confirm the operative side before sterile preparation and draping.

Sterile Preparation and Draping

Sterile prep and drape consists of a Surgical Sterile Drape Sheet (3M Health Care) being placed over the body caudal to the axilla of the operative extremity. The surgeon or circulating nurse then cleans the skin with Chloraprep (CareFusion, San Diego, CA) or other desired solution. The scrubbed surgical assistant can use a sterile towel to pull the operative extremity cranially, thus exposing the axilla for further cleaning with Chloraprep (CareFusion) or other desired solution. A sterile impervious U-Drape (9196 Shoulder Split Sheet with Pouch, 3M Health Care) is then placed across the neck and down the chest and back to isolate the sterile field, followed by a second impervious U-Drape across the axilla and up the chest and back. Another sterile green towel is folded lengthwise and wrapped around the nonsterile ACE elastic bandage, and then wrapped in sterile 3M Coban Wrap (3M Health Care) to maintain a sterile environment during the procedure. Two additional sterile drapes are placed, one with an arthroscopic fluid collection pocket and associated drain (1094 Arthroscopy Sheet with Pouch, 3M Health Care), are used to isolate the final sterile field. The drapes are secured using cut strips of Ioban (3M Health Care) to prevent drape creep and ensure the sterile field. Once

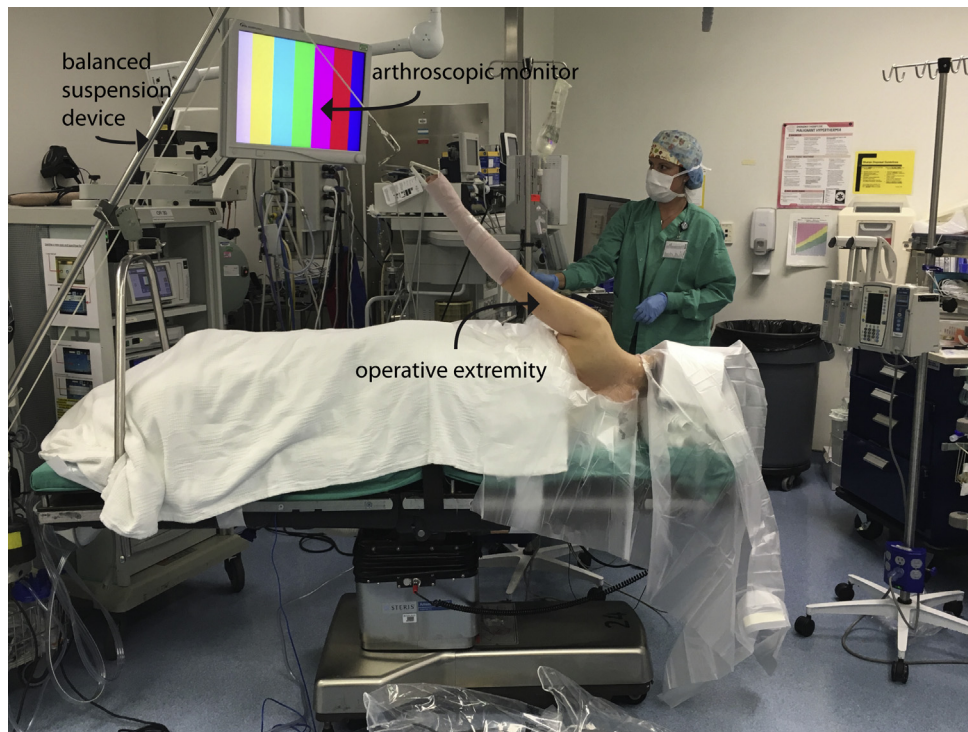


Fig 4. Patient positioned in the lateral decubitus position for a left shoulder arthroscopy before preparation and draping. Ten to 15 pounds of traction is placed on the operative (left) extremity to expose to the joint space.

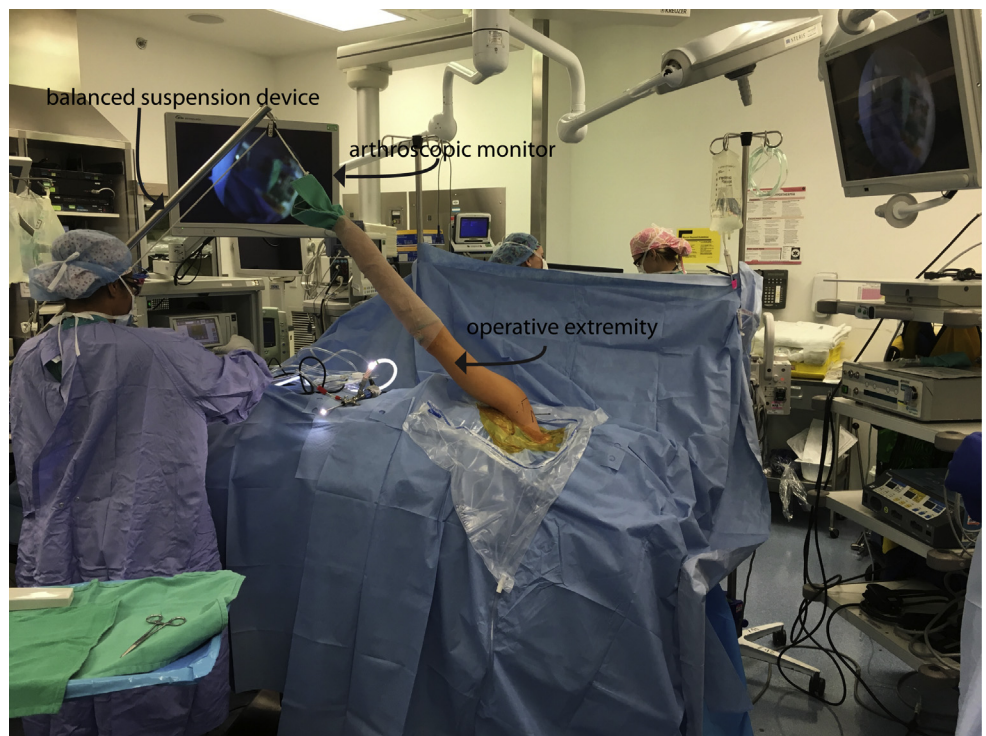


Fig 5. Patient positioned in the lateral decubitus position for a left shoulder arthroscopy after preparation and draping. The operative extremity (left) is held in traction before the procedure.

the patient is positioned, prepared, and draped (Fig 5), the surgical team changes gloves and conducts a final preincision timeout per our institutional protocol.

Discussion

Arthroscopy of the shoulder was first described in a cadaveric study in 1931 by Burman.⁹ In the early 1980s, authors began publishing case series using arthroscopy for diagnostic purposes.¹⁰⁻¹² In the last 35 years, shoulder arthroscopy has undergone tremendous evolution from a purely diagnostic procedure to a modern day technique to perform complex repairs and reconstructions.

There are 2 options for shoulder arthroscopy patient positioning: the beach chair and the lateral decubitus positions. Both positions have their merits (Table 2) and selection is largely based on surgeon preference.^{1,4-6} This note focuses on the lateral decubitus patient positioning. There are several key steps to the lateral decubitus positioning to avoid perioperative complications.

The most commonly reported complication of the lateral decubitus position is neuropraxia, with a reported incidence of 10% to 30%, which has been attributed to excessive strain on the brachial plexus due to intraoperative traction.^{4,5} Thus, it is important to minimize the traction during the procedure (we do not exceed 15 lb) to attenuate the forces on the neurovascular structures.^{1,13} Intraoperative assistance in distraction and visualization is often achieved with

a roll of towels placed between the arm and the torso. This additionally has the potential for neural compromise and subsequent neuropraxia. Ellman¹⁴ reported a neuropraxia rate of 7.5% that was attributed to poor padding during the setup for the lateral decubitus position; thus, the second key step is assuring that bony prominences are padded to prevent neuropraxias and excessive skin pressure. Finally, multiple authors identified a greater rate of thromboembolic events with patients in the lateral position compared with the beach chair position¹⁵⁻¹⁷; thus, the application of sequential compression devices at the beginning of the patient positioning process and ensuring their use during the surgical procedure is undertaken to help reduce the risk of deep vein thrombosis.

Table 2. A Comparison of the Merits of Lateral Decubitus Positioning and Beach Chair Positioning for Shoulder Arthroscopy

Lateral Decubitus	Beach Chair
<ul style="list-style-type: none"> • Increased access to the glenohumeral joint and subacromial space • Easier visualization and repair of all labral pathology • Better cerebral perfusion • More efficient setup time • Less fogging of camera • Cautery bubbles move laterally out of view 	<ul style="list-style-type: none"> • More anatomic positioning of the joint • Lower incidence of neuropathies • Decreased risk of neurovascular injury during portal placement • Easier conversion to an open procedure

Table 3. Advantages and Disadvantages of Lateral Decubitus Positioning for Shoulder Arthroscopy

Advantages	Disadvantages
<ul style="list-style-type: none"> • Increased access to the glenohumeral joint and subacromial space • Easier visualization and repair of labral pathology • Better cerebral perfusion • More efficient setup time • Less fogging of camera • Cautery bubbles move laterally out of view 	<ul style="list-style-type: none"> • Traction and inadequate padding may lead to neuropraxias • Inadequate padding of bony prominences may lead to soft tissue injuries • May need to redo preparation and draping if you need to convert to an open procedure • Placement of the anterior portal is mechanically challenging due to the operative arm being pulled by the balanced suspension device • Nonanatomic orientation of the joint • Need for general endotracheal anesthesia

Several advantages of the lateral decubitus position have been described in the literature. Anatomically, this position provides increased access to the glenohumeral joint and subacromial space, traction accentuates labral tears, and there is easier access to the posterior and superior shoulder.^{1,13,18,19} Moreover, a recent review of the literature by Frank et al.²⁰ showed instability recurrence rates in patients undergoing anterior shoulder stabilization to be significantly less in patients whose procedures were performed in the lateral decubitus position when compared with those performed in the beach chair position. It can be postulated that these results are due to the increased access to the anterior, inferior, and posterior glenoid in this position.

Other important merits of the lateral decubitus position include decreased camera fogging and cautery bubble collection, a lower risk of hypotension and/or bradycardia, and a more efficient setup time.^{1,13,18,21,22} These will decrease the risk to the patient by improving visualization for the surgeon intraoperatively and decreasing the risk for cerebral hypoperfusion, while potentially decreasing costs by reducing operating room time.

However, supporters of the beach chair position point out the nonanatomic orientation, difficult placement of the anterior portal, and inability to convert to an open procedure without repositioning and redraping.²³ Furthermore, there is an increased risk for neurovascular and soft tissue injury with traction, and an increased risk of injury to the axillary and musculocutaneous nerves when placing the anteroinferior portal.^{1,13,24} The final disadvantage that corresponds with the lateral decubitus position is that it will typically require general anesthesia because regional anesthesia is not well tolerated.^{20,25} See Table 3 for a list of advantages and disadvantages of using the lateral decubitus position for shoulder arthroscopy.

In conclusion, optimal preoperative patient positioning with a reproducible technique is required to assure patient safety and limit complications. Proper patient positioning requires the assistance and expertise of the entire operating room team, including the surgeon, surgical assistants, nursing staff, surgical technologists, and the anesthesia staff. If the surgical team is

knowledgeable in the positioning and sterile preparation for shoulder arthroscopy in the lateral decubitus position, the efficiency of the operative procedure will be maximized and operative risk to the patient will be minimized.

References

1. Peruto CM, Ciccotti MG, Cohen SB. Shoulder arthroscopy positioning: Lateral decubitus versus beach chair. *Arthroscopy* 2009;25:891-896.
2. Carr AJ, Price AJ, Glyn-Jones S, Rees JL. Advances in arthroscopy-indications and therapeutic applications. *Nat Rev Rheumatol* 2015;11:77-85.
3. Farmer KW, Wright TW. Shoulder arthroscopy: The basics. *J Hand Surg Am* 2015;40:817-821.
4. Li X, Eichinger JK, Hartshorn T, Zhou H, Matzkin EG, Warner JP. A comparison of the lateral decubitus and beach-chair positions for shoulder surgery: Advantages and complications. *J Am Acad Orthop Surg* 2015;23:18-28.
5. Skyhar MJ, Altchek DW, Warren RF, Wickiewicz TL, O'Brien SJ. Shoulder arthroscopy with the patient in the beach-chair position. *Arthroscopy* 1988;4:256-259.
6. Burkhart SS, Lo IKY, Brady PC, Denard PJ. *The cowboy's companion: A trail guide for the arthroscopic shoulder surgeon*. Philadelphia, PA: Lippincott Williams & Wilkins, 2012.
7. Songur M, Sahin E. A simple traction assembly for shoulder arthroscopy in lateral decubitus position: A cost-effective alternative. *Arthrosc Tech* 2015;4:e341-e343.
8. Oh JH, Kim JY, Chung SW, et al. Warmed irrigation fluid does not decrease perioperative hypothermia during arthroscopic shoulder surgery. *Arthroscopy* 2014;30:159-164.
9. Burman MS. Arthroscopy or the direct visualization of joints: An experimental cadaver study. 1931. *Clin Orthop Relat Res* 2001;390:5-9.
10. Wiley AM, Older MW. Shoulder arthroscopy. Investigations with a fiberoptic instrument. *Am J Sports Med* 1980;8:31-38.
11. Bunker T. Shoulder arthroscopy. *Ann R Coll Surg Eng* 1989;71:213-217.
12. Cofield RH. Arthroscopy of the shoulder. *Mayo Clin Proc* 1983;58:501-508.
13. Paxton ES, Backus J, Keener J, Brophy RH. Shoulder arthroscopy: Basic principles of positioning, anesthesia, and portal anatomy. *J Am Acad Orthop Surg* 2013;21:332-342.

14. Ellman H. Arthroscopic subacromial decompression: Analysis of one- to three-year results. *Arthroscopy* 1987;3: 173-181.
15. Garofalo R, Notarnicola A, Moretti L, Moretti B, Marini S, Castagna A. Deep vein thromboembolism after arthroscopy of the shoulder: Two case reports and a review of the literature. *BMC Musculoskelet Disord* 2010;11:65.
16. Kuremsky MA, Cain EL Jr, Fleischli JE. Thromboembolic phenomena after arthroscopic shoulder surgery. *Arthroscopy* 2011;27:1614-1619.
17. Burkhart SS. Deep venous thrombosis after shoulder arthroscopy. *Arthroscopy* 1990;6:61-63.
18. Rains DD, Rooke GA, Wahl CJ. Pathomechanisms and complications related to patient positioning and anesthesia during shoulder arthroscopy. *Arthroscopy* 2011;27: 532-541.
19. Baechler MF, Kim DH. Patient positioning for shoulder arthroscopy based on variability in lateral acromion morphology. *Arthroscopy* 2002;18:547-549.
20. Frank RM, Saccomanno MF, McDonald LS, Moric M, Romeo AA, Provencher MT. Outcomes of arthroscopic anterior shoulder instability in the beach chair versus lateral decubitus position: A systematic review and meta-regression analysis. *Arthroscopy* 2014;30:1349-1365.
21. Meex I, Genbrugge C, De Deyne C, Jans F. Cerebral tissue oxygen saturation during arthroscopic shoulder surgery in the beach chair and lateral decubitus position. *Acta Anaesthesiol Belg* 2015;66:11-17.
22. Meex I, Vundelinckx J, Buyse K, et al. Cerebral tissue oxygen saturation values in volunteers and patients in the lateral decubitus and beach chair positions: A prospective observational study. *Can J Anaesth* 2016;63:537-543.
23. Maier D, Izadpanah K, Jaeger M, Ogon P, Sudkamp NP. Tenoscopic suprapectoral biceps tenodesis. *Arthrosc Tech* 2016;5:e55-e62.
24. Gelber PE, Reina F, Caceres E, Monllau JC. A comparison of risk between the lateral decubitus and the beach-chair position when establishing an anteroinferior shoulder portal: A cadaveric study. *Arthroscopy* 2007;23:522-528.
25. Koh JL, Levin SD, Chehab EL, Murphy GS, Neer Award 2012: Cerebral oxygenation in the beach chair position: A prospective study on the effect of general anesthesia compared with regional anesthesia and sedation. *J Shoulder Elbow Surg* 2013;22:1325-1331.