

# A Critical Review

## Management and Surgical Options for Articular Defects in the Hip

Eric C. Makhni, MD, MBA<sup>a</sup>, Austin V. Stone, MD, PhD<sup>b</sup>,  
Gift C. Ukwuani, MD<sup>c</sup>, William Zuke, BS<sup>c</sup>,  
Tigran Garabekyan, MD<sup>d</sup>, Omer Mei-Dan, MD<sup>e</sup>,  
Shane J. Nho, MD, MS<sup>c,\*</sup>

### KEYWORDS

- Chondral injury • Osteochondral autologous transplantation
- Osteochondral allograft transplantation • Autologous chondrocyte transplantation
- Mosaicplasty • Viscosupplementation

### KEY POINTS

- Nonoperative treatment continues to be the mainstay of treatment for patients with articular cartilage lesions of the hip.
- There is a heterogeneity of support in the scientific literature regarding efficacy of biologic injections for cartilage disease of the hip.
- Treatment algorithms for focal cartilage disease of the hip resemble those for the knee.

### INTRODUCTION

Despite significant research and investigative efforts, the optimal management of articular cartilage injury remains a challenge in orthopedic sports medicine [Table 1](#). Although much of the research in articular cartilage injuries has occurred in the knee, the recent rapid growth of the hip preservation field, has caused an increase

---

Disclosures. Nothing to disclose (E.C. Makhni, T. Garabekyan, G.C. Ukwuani, W. Zuke); Smith and Nephew: Research support (A.V. Stone); MITA: Stock or stock Options, Smith & Nephew: Paid consultant; Research support (O. Mei-Dan).

<sup>a</sup> Division of Sports Medicine, Department of Orthopedic Surgery, Henry Ford Health System, 6777 West Maple Road, 3rd Floor East, West Bloomfield, MI 48322, USA; <sup>b</sup> Department of Orthopedic Surgery, Wake Forest School of Medicine, Medical Center Boulevard, Winston-Salem, NC 27157-1070, USA; <sup>c</sup> Division of Hip Preservation Surgery, Rush University Medical Center, 1611 West Harrison Street, Chicago, IL 60612, USA; <sup>d</sup> Southern California Hip Institute, 10640 Riverside Drive, North Hollywood, CA 9160, USA; <sup>e</sup> CU Sports Medicine and Performance Center, University of Colorado, 2150 Stadium Drive, Boulder, CO 80309, USA

\* Corresponding author.

E-mail addresses: [shane.nho@rushortho.com](mailto:shane.nho@rushortho.com); [nho.research@rushortho.com](mailto:nho.research@rushortho.com)

Clin Sports Med ■ (2017) ■–■

<http://dx.doi.org/10.1016/j.csm.2017.02.010>

[sportsmed.theclinics.com](http://sportsmed.theclinics.com)

0278-5919/17/© 2017 Elsevier Inc. All rights reserved.

**Table 1**  
**Outerbridge classification system for chondromalacia**

**Grade**

0	Normal cartilage
1	Softening and swelling of the cartilage
2	Partial-thickness defect with surface fissuring that does not extend to the subchondral bone and is <1.5 cm in diameter
3	Partial-thickness defect with surface fissures extending to the subchondral bone or >1.5 cm in diameter
4	Full-thickness cartilage defect

*Data from Outerbridge RE. The etiology of chondromalacia patellae. J Bone Joint Surg Br 1961;43-B:752–7.*

in similar emphasis in the hip. The difficulty in treating chondral injury is a direct consequence of the tissue's limited repair capacity. When present in patients undergoing hip arthroscopy for femoroacetabular impingement (FAI) or hip dysplasia, these chondral injuries may be associated with significant pain and decreased patient-reported outcome (PRO) scores when compared with patients without these lesions.<sup>1</sup> Therefore, knowledge of the wide variety of treatment options for these lesions is essential when caring for these patients. Fortunately, many common treatment strategies for articular cartilage lesions in the hip have been adopted from those previously used in the knee, at times with improved success rates due to better joint congruency. These have produced varying degrees of success.<sup>1–4</sup> The goal of this review was to provide an overview of both the nonoperative and operative treatment options for articular cartilage lesions of the hip. The ultimate goal of this treatment is not only to mitigate pain and disability, but also to minimize progression of disease.

## CLINICAL PRESENTATION AND DIAGNOSTIC EVALUATION

Patients with articular cartilage lesions of the hip may present with pain and symptoms that may be vague in nature and onset. Often, there may be no discrete event or injury that can be recalled. Therefore, a thorough history and physical examination should be performed for every patient presenting with hip pain and/or disability. Pain is often a chief complaint; therefore, the pain should be described with respect to the nature and location of the pain, exacerbating activities or positions, timing of onset, and position or treatment that provides relief. It is important to identify additional medical comorbidities, patient-specific work or activity-related injuries, or predisposing factors, as these may elucidate concomitant pathologies. Certain sporting activities are known to be associated with chondral injury.<sup>5–9</sup> As with every patient presenting with hip pain or symptoms, other sources of injury must be ruled out, such as lumbo-sacral, urologic, neurologic, or surrounding mimickers that can be perceived as hip pain, such as piriformis syndrome, abductors or adductor tears, and others.

Many patients presenting with FAI have concomitant chondral injury associated with the underlying bony defect. In true pincer-type deformities, the extent of soft tissue injury may be confined to the labrum or be diffuse, causing degeneration, whereas those with CAM deformities are more prone to present with chondral delamination or shear injuries. It is our experience, though, that most patients have a mixed deformity, and as such can suffer from both types of cartilage injuries.

### ***Physical Examination and Imaging Findings***

Physical examination is performed in conjunction with thorough history. The examination begins with assessment of patient gait, as we are careful to note existence of any evidence of antalgic gait or abductor lurch. Following gait assessment, laxity evaluation, and standing spinal examination, the patient is positioned supine on the examination table. Any points of tenderness are elicited, such as over the pubic symphysis, groin, ischial tuberosity, or greater trochanter. Both the injured hip, as well as the asymptomatic hip for comparison, are brought through full range of motion arcs in flexion, extension, external rotation, and internal rotation, both in hip flexion and natural hip. Strength is assessed in flexion, extension, and abduction. Finally, provocative maneuvers are then performed. These include impingement testing in the flexion, adduction, and internal rotation position (FADIR). Reproducible pain in this position is often associated with impingement, labral tear, and/or corresponding chondral injury. Dysplastic patients may have a positive test in the setting of labral tear but without impingement. Pain in the FABER position (flexion, abduction, and external rotation) may represent sacro-iliac pathology or posterior impingement if elicited posteriorly but if pain is elicited in the front, this would correspond with inflamed joint or early osteoarthritis. Resisted abduction is performed to elicit any abductor tendinitis or weakness indicative of a tear. Additional tests include lateral rim impingement test, in which pain is elicited with abduction of the hip, indicative of lateral overcoverage, as well as instability tests, which are particularly helpful in patients who have ligamentous laxity or pain following prior hip arthroscopy with possible capsular insufficiency.

Radiographic data may additionally aid in the diagnosis of chondral injury in the hip. Routine imaging includes a plain radiograph series consisting of an anteroposterior pelvis, Dunn lateral, and false profile. Radiographs may be limited in the ability to detect focal chondral disease, and so MRI is routinely used to assess the soft tissue structures. Bony deformity and dysplasia is best visualized with a 3-dimensional computed tomography (CT) scan. CT scans also may help demonstrate subchondral cysts that must be identified before surgery. Although the gold standard for diagnosis of chondral lesions remains direct visualization with hip arthroscopy, certain lesions (eg, cysts) require close inspection on preoperative advanced imaging, as these lesions may not be readily evident on “surface” visualization. Direct visualization of the lesion affords accurate measurement of the size, as well as classification, according to any number of cartilage grading systems.

There are several cartilage grading systems available. The Outerbridge classification system is most commonly used and is reproducible and reliable.<sup>10,11</sup> Two less commonly used systems include the Beck classification<sup>12</sup> and the acetabular labrum articular disruption classification.<sup>13</sup>

## **MANAGEMENT OF PATIENTS WITH CHONDRAL INJURY OF THE HIP**

### ***Nonoperative Treatment***

Nonoperative treatment remains the mainstay of management for patients with articular cartilage injury of the hip, especially on initial presentation. Initial treatment consists of a trial of rest and/or activity modification, along with anti-inflammatory medications and physical therapy. This treatment protocol may be initiated on clinical diagnosis, along with review of plain radiographs, before obtaining advanced imaging. In our practice, we typically obtain advanced imaging (noncontrast MRI) in patients who fail to respond to treatment after 4 to 6 weeks. When the diagnosis of FAI is confirmed along with possible chondral injury, an intra-articular injection is then

offered. This injection is both diagnostic and therapeutic, and response is measured through a postinjection pain diary. Injections are particularly helpful in distinguishing pain sources as being from the hip as opposed to other anatomic sites. A recent systematic review by Lynch and colleagues<sup>14</sup> reported that improved pain relief may be experienced in patients with acetabular chondral injury when compared with those patients with impingement or labral pathology. However, this period of relief may be limited, with recurrence of pain within weeks or months following injection. It is our experience that patients who are older and who may have early degenerative disease, and therefore a large contribution of inflammatory-mediated pain, may experience a longer period of relief than those patients without such findings.

### ***Biologic Injections***

A variety of biologic injections exist for treatment of focal and diffuse chondral disease of the hip. These include hyaluronic acid, platelet rich plasma (PRP), and stem cell therapy. Unfortunately, there is still a lack of high-level evidence regarding the efficacy of these treatments in the hip. Moreover, many of the published trials are focused on treatment of hip osteoarthritis, as opposed to focal chondral defects. These studies have demonstrated some benefit to viscosupplementation,<sup>15,16</sup> but these benefits have not been proven in other trials when compared with saline injection.<sup>17,18</sup> Similarly, only limited evidence for PRP exists in this setting. Further studies in patients with focal chondral defects are necessary, however.

### **SURGICAL OPTIONS FOR CHONDRAL DEFECTS OF THE HIP**

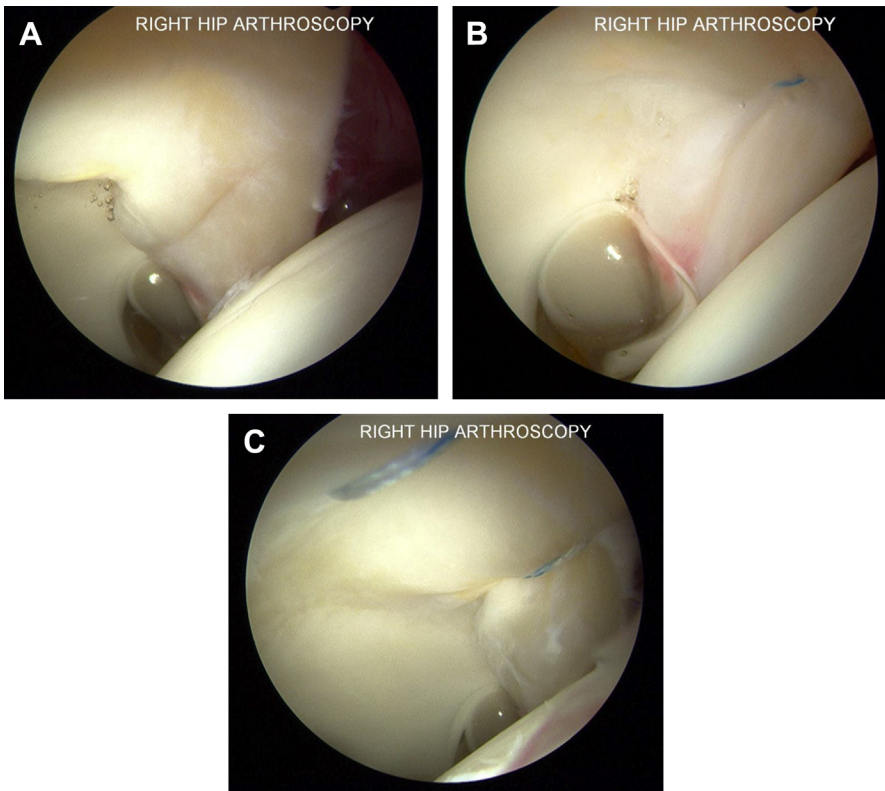
As with the knee, it is our preference to use an algorithm-based approach when considering surgery for cartilage defects of the hip (once all nonoperative treatments have failed). Similar to the knee, the first factor to consider is bony “alignment” of the hip joint; namely, the articulation of the acetabular rim with the femoral head/neck junction. Any treatment of cartilage injury from underlying FAI should be addressed intraoperatively, through a removal of the pincer lesion (acetabular rim trimming) and CAM lesion (femoral osteochondroplasty) as evident by preoperative imaging. In cases of significant dysplasia, consideration for a combined arthroscopic and open surgery should be considered for appropriate osteotomy along with the cartilage/labral repair. Second, the stability of the hip should be assessed, especially when considering revision scenarios. It is our experience that many patients with secondary hip instability following initial arthroscopy may experience persistent (or even worse) pain when compared with preoperatively. These symptoms are typically due to lack of a capsular repair during index surgery, or incomplete healing. Therefore, any surgical treatment should consist of capsular repair (or reconstruction if necessary). Finally, the cartilage lesion itself must be addressed, and this can be done according to any of the treatments described as follows.

Articular cartilage defects in the hip may be treated using open<sup>19–25</sup> or arthroscopic techniques.<sup>3,4,6,7,23,26–36</sup> Arthroscopic surgery of the hip continues to grow in popularity for diagnosing and managing articular cartilage injury. Hip arthroscopy demonstrates select advantages for treatment of chondral injury (without significant dysplasia) over open treatment due to improved physical visualization of intra-articular pathology and increased speed of recovery with less soft tissue injury.<sup>28</sup> Open surgery may be warranted as an adjunctive procedure if significant dysplasia or deformity exists. The current arthroscopic techniques for treating hip chondral damage include chondroplasty, microfracture,<sup>4,6,7,26,29,30,32–34,37,38</sup> fibrin adhesives,<sup>35,36</sup> and autologous chondrocyte transplantation (ACT).<sup>27,28,31</sup> Open treatment consists

of osteochondral autologous transplantation (OAT) and mosaicplasty,<sup>39</sup> along with osteochondral allograft transplantation.

### **Chondroplasty**

Chondroplasty, or abrasion arthroplasty, is a long-standing debridement technique for partial-thickness chondral lesions that is commonly performed as a component of arthroscopy.<sup>40,41</sup> The primary goal of chondroplasty is to prevent further chondral destabilization, pain, and mechanical symptoms by resultant chondral flaps. These injuries typically occur as a result of shearing at the chondrolabral junction, often producing a “wave” sign and later a true cartilage flap. This represents a delamination of the cartilage from the underlying subchondral bone. It is our practice to attempt to keep the cartilage grossly intact despite this delamination, when possible, as opposed to unroofing and debriding the defect. Once debrided, there often remains an area of full-thickness, Grade IV cartilage injury that requires further treatment, and often microfracture (see the next section). Alternatively, when concomitant labral pathology exists, it is our preference to try to incorporate the cartilage delamination into the repair construct (Fig. 1), with the goal of eventual stabilization and healing. Additionally, anchor placement adjacent to the articular cartilage delamination is thought to induce bleeding behind the cartilage and stimulate a healing response.



**Fig. 1.** Incorporation of cartilage delamination (A) into labral repair construct (B, C), left hip. Note the prominent “wave sign” indicating cartilage delamination from the underlying FAI. (Courtesy of Dr Shane J. Nho, Chicago, IL.)

### Microfracture

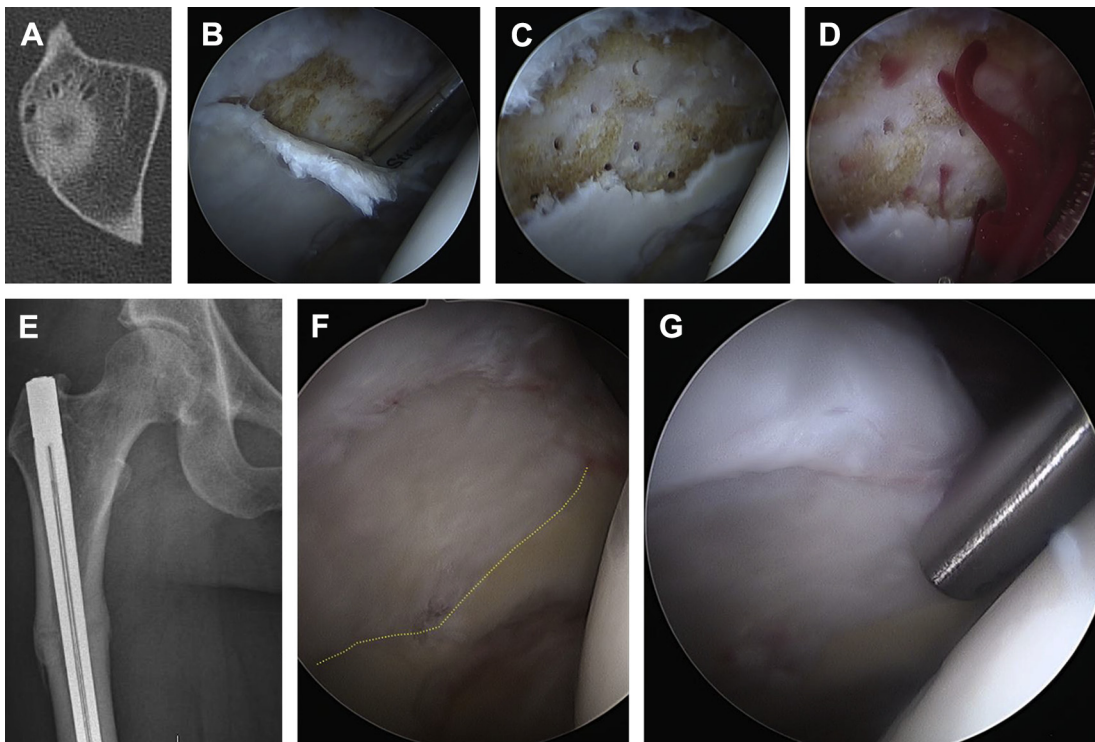
Microfracture is a widely used technique in the knee that has seen widespread use for the management of chondral defects in the hip.<sup>1,4,6,7,26,29,30,32–34,37,38,42–45</sup> The indications for microfracture in the reported techniques follow those described in the knee,<sup>44,45</sup> and are rapidly evolving in their use in the femoral head and acetabulum.<sup>4,32,38,46</sup> Classically, in the knee, microfracture is indicated in for full-thickness chondral lesions measuring less than 2 cm<sup>2</sup> with corresponding good to excellent clinical results.<sup>44,45</sup> In our practice, microfracture in the hip is a first-line treatment for full-thickness cartilage defects provided there is a stable rim of cartilage surrounding the defect.

The same values have been recommended in the hip for focal, full-thickness defect of less than 2 cm<sup>2</sup> and minimal radiographic arthritis (Tönnis grade 0–1)<sup>8,26,29,30,32–34,47</sup>; however, a recent case series has suggested full-thickness defects of up to 7.50 cm<sup>2</sup> may be effectively managed with microfracture.<sup>4</sup> The investigators further advocate that hip arthroscopy may be used in older patients with Tönnis grade 0 or 1 despite good to excellent results in 60% at 2-year follow-up.<sup>4</sup> Patients with Tönnis grade 2 changes demonstrate increased conversion to total hip arthroplasty at 2 years following hip arthroscopy; consequently Tönnis grade 2 is considered a relative exclusion criteria.<sup>48</sup>

Microfracture can be performed during hip arthroscopy in the standard supine position, as previously described.<sup>38</sup> The patient history and physical, combined with pre-operative imaging, should guide the surgeon's diagnostic arthroscopy. Once the chondral lesion is identified, unstable cartilage should be removed from the subchondral bone (Fig. 2). A ring curette may then be used to create a perpendicular edge from the defect's subchondral bone to the healthy cartilage to contain the marrow clot during microfracture, thereby removing the layer of calcified cartilage. The subchondral bone is then perforated with microfracture awls. Acetabular microfracture also may be accomplished with the use of flexible drills,<sup>46</sup> which may provide improved perpendicular access to lesions. Regardless of technique, a bleeding response should be confirmed from the subchondral bone to ensure adequate penetration.<sup>32,46</sup> Depth of penetration should be 4 mm with perforations spaced at least 2 to 3 mm apart to avoid fracture of the subchondral plate.

Reported outcomes demonstrate that microfracture is an effective technique for managing full-thickness chondral defects. Karthikeyan and colleagues<sup>30</sup> found that in their 20-patient series with a mean age of 37 years and a mean chondral defect of 154 mm<sup>2</sup> treated with microfracture, 19 of 20 patients demonstrated a mean 96% filling of the microfracture defect at second-look arthroscopy. Philippon and colleagues<sup>34</sup> reported similar defect fillings of 95% to 100% at the time of second-look arthroscopy in their 9-patient series with a mean age of 37 years and mean acetabular defect of 1.63 cm<sup>2</sup>. Microfracture for patients with full-thickness chondral defects continue to do well at 3 years postoperatively when compared with a matched cohort that did not undergo microfracture.<sup>43</sup> A 35-patient cohort with a full-thickness chondral defect that underwent hip arthroscopic chondral microfracture was matched to a 70-patient cohort that did not undergo microfracture.<sup>43</sup> No statistical differences were found in PROs between the groups. A recent systematic review by MacDonald and colleagues<sup>32</sup> examined microfracture as an adjunct treatment for chondral defects in FAI and identified positive outcomes in 266 of 267 patients. The complication rate was 0.7%, and 1.1% required revision surgery. Microfracture may be effective (see Fig. 2) even in large lesions (>2 cm<sup>2</sup>) and in older patients (>50 years) rather than limited to more conventional lesion sizes (<2 cm<sup>2</sup>).<sup>4</sup> Continued exploration of the techniques and outcomes for microfracture may result in expanded indications for microfracture treatment.





**Fig. 2.** Microfracture of large acetabular chondral defect. Right hip with evidence of cystic and cartilage disease (A) due to femoral retro-torsion and CAM type FAI with corresponding arthroscopic appearance (B) undergoing labral reconstruction. After debridement of the unstable cartilage flap, the defect was microfractured using a drill (Stryker, Phoenix, AZ) (C), with evidence of bleeding subchondral bone indicating adequate microfracture (D). A derotational osteotomy was then performed to correct (–15) degrees of femoral torsion to normal values (E). Corresponding images with second-look arthroscopy, demonstrating well-incorporated reconstructed labrum (tensor fascia lata [TFL] allograft) with excellent fill of the defect (F, G) in setting of prior procedure. (Courtesy of Dr Omer Mei-Dan, Boulder, CO.)

### ***Autologous Chondrocyte Transplantation***

ACT is an evolving treatment strategy for cartilage repair. ACT is a 2-stage operation that extracts viable chondrocytes, cultures them in a laboratory setting, and finally reimplants the chondrocytes in a second surgical procedure. Reimplantation techniques vary, but like microfracture techniques, ACT for the hip has been adopted from the knee literature.<sup>49–52</sup> An alternative to ACT is autologous matrix-induced chondrogenesis (AMIC), which is a single-stage procedure to attempt recreation of hyaline cartilage.<sup>53</sup> The indications for performing ACT and AMIC are classically a larger chondral defect (3 cm<sup>2</sup> or larger) with a focal, full-thickness Outerbridge grade 3 or 4 defect and minimal radiographic evidence of osteoarthritis (Tönnis 1 or less).<sup>1,27,28,31</sup> In comparison with the microfracture literature, a systematic review recently identified that lesions in the hip treated with arthroscopic ACT were significantly larger than those treated with microfracture.<sup>1</sup> As the techniques and technologies continue to advance, the indications may be expanded for autologous chondrocyte transplantation and chondrogenesis techniques.

Arthroscopic technique for ACT in the hip may be performed after routine hip arthroscopy and in conjunction with additional procedures. Fontana and colleagues<sup>28</sup> described taking an initial cartilage sample at the time of diagnostic arthroscopy. Following a 30-day incubation period, the patient returns for a second operation in which the chondral lesion is prepared with debridement and a chondrocyte culture on bioresorbable 3-dimensional scaffolding is prepared for implantation. The graft is cut precisely to fit the defect and introduced arthroscopically.<sup>28</sup> Alternative scaffolds also have been described and the implantation techniques are similar.<sup>27,31</sup> The AMIC technique, which is similar to ACT, is described as a single-stage operation.<sup>53</sup> In AMIC, the chondral defect is again arthroscopically debrided in a standard fashion but microfracture is then performed. After microfracture of the defect, a bioresorbable scaffolding is placed over the microfracture defect.<sup>53</sup>

Outcomes for ACT and AMIC are promising. In a case-control comparison between ACT and AMIC, the modified Harris Hip Score (mHHS) was statistically improved at 5-year follow-up in both groups but the improvement was not statistically different between groups.<sup>53</sup> The mean defect size was  $2.8 \pm 0.7$  cm<sup>2</sup> in the ACT group ( $n = 26$ ) and  $2.9 \pm 0.8$  cm<sup>2</sup> in the AMIC group ( $n = 31$ ).<sup>53</sup> Subgroup analysis demonstrated successful improvement in both groups for defect sizes greater than 3 cm<sup>2</sup>, and the investigators concluded that AMIC could be effectively applied to larger defects.<sup>53</sup> Fickert and colleagues<sup>27</sup> reported that 3-dimensional ACT could be effective for larger defects (mean 3.5 cm<sup>2</sup>) at 1-year follow-up as measured by significant and maintained improvements in the Nonarthritic Hip Score (NHS), mHHS, and Short Form (SF)-36 scores. A smaller case series ( $n = 6$ ) reported on arthroscopic 3-dimensional ACT reported similar improvement to Fickert and colleagues<sup>27</sup> as measured by NHS and WOMAC scores. With further development of AMIC, ACT may become less desirable due to its staged requirement; however, both techniques demonstrate optimistic early results.

### ***Cartilage Repair***

Fibrin adhesive is a proposed option for arthroscopic repair of chondral delamination.<sup>35,36</sup> The initial results are promising; however, the patient series are small. Stafford and colleagues<sup>35</sup> treated 43 hips with chondral delamination by microfracturing under the flap and securing the flap with fibrin glue. At 28 months of follow-up, the pain and function mHHS subscales remained improved. Tzaveas and Villar<sup>36</sup> treated delaminated cartilage injury arthroscopically with fibrin glue. At 1-year follow-up, the mHHS overall and pain scores remained improved. Sekiya and colleagues<sup>54</sup> reported



a single case in which a 1-cm<sup>2</sup> chondral flap was secured with suture after microfracture. The mHHS and Hip Outcome Score (HOS)–Activities of Daily Living and HOS–Sport-Specific Subscales were improved at 2 years.<sup>54</sup> A recent biomechanical study in cadavers examining arthroscopic chondral repair techniques identified early biomechanical failure in fibrin adhesive repair, which failed after only 50 cycles.<sup>55</sup> The same study evaluated suture repair of chondral flaps and found that it was stable throughout the 1500-cycle testing regimen.<sup>55</sup> The small number of reported outcomes and early laboratory failure may limit fibrin's clinical use; however, both fibrin glue and suture repair warrant further investigation.

### ***Bone Grafting and Osteochondral Grafting for Osteochondral Defects of the Hip***

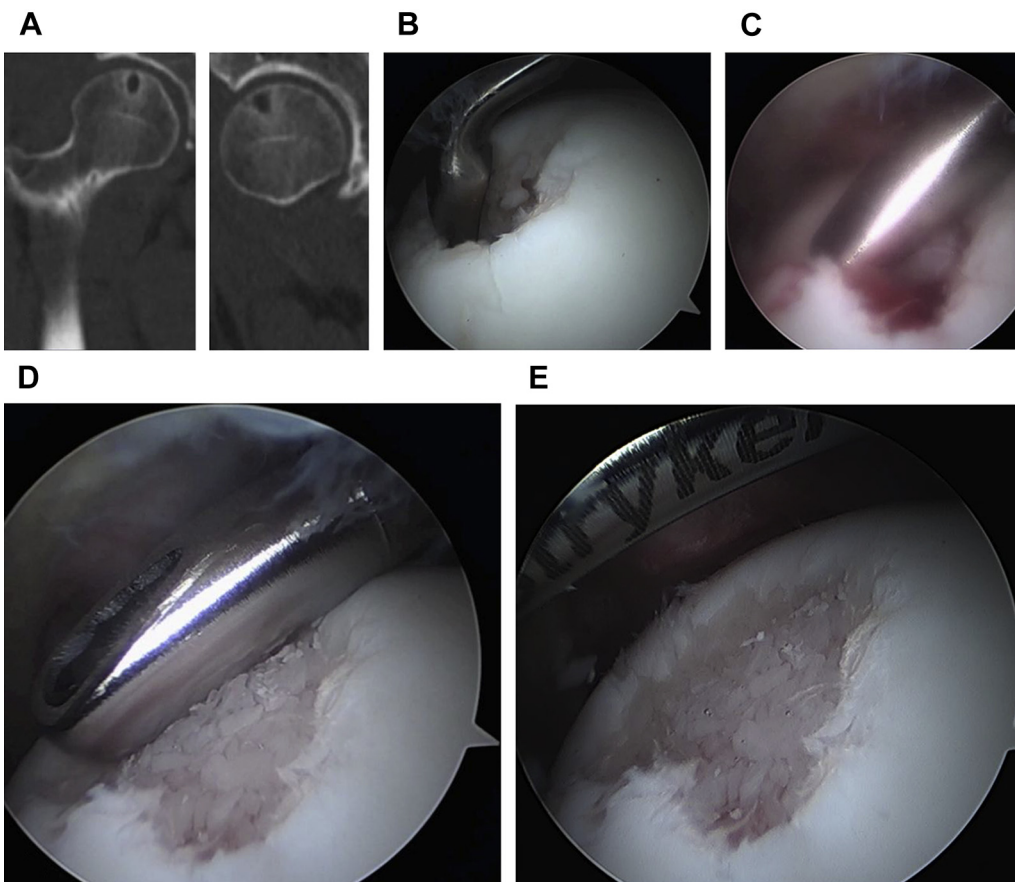
Many of the previously described techniques are well-suited for chondral disease that spares the subchondral plate; however, when large (>0.5 cm<sup>2</sup>) full-thickness osteochondral defects are present, treatment should be directed at bone-grafting procedure. Traditionally, osteochondral autograft or allograft transplantation offer an alternative to ACT and AMIC for larger osteochondral defects. This approach is described in the following paragraphs. However, one of the senior authors (O.M.-D.) from this group has described a technique for bone grafting of large osteochondral defects that may be performed as a primary procedure. Although this technique does not provide cartilage transplantation, it does serve as an initial procedure that may obviate the need for an open dislocation of the hip and good bone fill, enabling a good base for cartilage growth.<sup>56</sup>

In this procedure,<sup>56</sup> the lesion is identified and debrided completely, exposing the overlying subchondral bone. A microfracture awl (XL Microfracture awl; Smith and Nephew, Andover, MA) is used to penetrate and probe the defect, thus exposing the underlying cyst and bone defect. A drill (Micro FX; Stryker, Phoenix, AZ) is used to incite bleeding and eventual healing from the base of the cyst. A curved shaver (4.5-mm curved shaver 30° Double Bite; Stryker, Kalamazoo, MI) is then used with the central blade portion removed and subsequent packing of bone graft (DBZ; Synthes, Westchester, PA) into the outer barrel. The removed inner blade is then used to impact the graft into the defect with precision. This technique may be used in the acetabular side (as described in the referenced technique article<sup>56</sup>), or in the femoral head, as seen in [Fig. 3](#).

Unlike microfracture, ACT, and AMIC, osteochondral grafting requires surgical dislocation of the hip. The indications have been adopted from the knee literature<sup>22,42,57–60</sup> and include larger osteochondral defects in patients with Tönnis grade 0 or 1 disease. Mosaicplasty is similar to OAT, but combines multiple plugs for larger defects. This treatment strategy has been applied to multiple diseases and trauma due to its ability to manage larger defects.<sup>1,19,20</sup>

The technique for OAT and mosaicplasty is adopted from the knee. Meyers<sup>60</sup> reported using fresh osteochondral allograft in hips with osteonecrosis. The cylindrical allograft was selected and press-fit to match the articular contour of the femoral head similar to the technique used for the knee.<sup>60</sup> Krych and colleagues<sup>22</sup> used a comparable OAT technique for acetabular defects. Mosaicplasty is usually performed with autologous osteochondral grafts and multiple cylindrical plugs are combined to fill larger lesions. Emre and colleagues<sup>19</sup> describe the use of osteochondral autograft to treat an osteochondral lesion in the femoral head through a standard Smith-Peterson approach and surgical dislocation. Autologous plugs may be taken from the ipsilateral knee through a mini-open approach.<sup>19</sup>

Outcomes for OAT and mosaicplasty demonstrate improvement, but are associated with greater morbidity in comparison with the arthroscopic techniques as a



**Fig. 3.** Bone grafting of a femoral head cyst using a curved shaver. Large cystic lesion noted in the femoral head on preoperative CT images (A) with intraoperative debriement and curettage pictures (B). Bone grafting delivered through curved shaver using technique referenced and described by senior author (OMD) (C, D). Final appearance of cystic lesion with bone grafting (E). (Courtesy of Dr Omer Mei-Dan, Boulder, CO.)

result of the surgical dislocation and autologous donor site. A case report by Evans and Providence<sup>61</sup> reported success in a femoral head fresh OAT with full painless range of motion at 1-year follow-up, although the report was limited to 1 patient. The 2 patients with OAT for acetabular lesions reported by Krych and colleagues<sup>22</sup> remained improved at 2-year and 3-year follow-ups with respective mHHS scores of 97 and 100.

Mosaicplasty outcomes in the hip are also limited and primarily confined to case reports and small case series. Nam and colleagues<sup>24</sup> and Hart and colleagues<sup>21</sup> reported on a total of 3 patients treated with mosaicplasty and saw return to activities without pain. In 1 series of 10 patients with large femoral head lesions by Girard and colleagues,<sup>62</sup> at more than 2 years postoperatively, the mean HHS was maintained at 80, increased from 53 preoperatively. OAT and mosaicplasty are technically demanding and have increased morbidity in the hip compared with the knee, which have limited their use and their outcomes reporting. These treatments may remain an effective strategy for treating large osteochondral lesions in the femoral head and acetabulum in patients without radiographic evidence of osteoarthritis.

## SUMMARY

The management of articular cartilage defects in the hip remains a challenging but very important area of rapidly evolving treatment strategies. As the understanding of cartilage biology continues to grow, nonoperative and operative techniques will likely involve a greater biologic focus. Arthroscopic techniques continue to decrease morbidity and offer innovative solutions and new applications for microfracture, ACT, and AMIC. This may be especially true with cystic conditions of the acetabulum or femoral head that may benefit from bone grafting arthroscopically, as referenced and illustrated in this article. The indications for cartilage-preserving techniques continue to expand and new biologics offer innovative solutions that may provide benefit to the patient.

## REFERENCES

1. Marquez-Lara A, Mannava S, Howse EA, et al. Arthroscopic management of hip chondral defects: a systematic review of the literature. *Arthroscopy* 2016;32(7):1435–43.
2. Bedi A, Feeley BT, Williams RJ 3rd. Management of articular cartilage defects of the knee. *J Bone Joint Surg Am* 2010;92(4):994–1009.
3. Lubowitz JH. Editorial commentary: microfracture for focal cartilage defects: is the hip like the knee? *Arthroscopy* 2016;32(1):201–2.
4. Trask DJ, Keene JS. Analysis of the current indications for microfracture of chondral lesions in the hip joint. *Am J Sports Med* 2016;44(12):3070–6.
5. Guanche CA, Sikka RS. Acetabular labral tears with underlying chondromalacia: a possible association with high-level running. *Arthroscopy* 2005;21(5):580–5.
6. McDonald JE, Herzog MM, Philippon MJ. Return to play after hip arthroscopy with microfracture in elite athletes. *Arthroscopy* 2013;29(2):330–5.
7. McDonald JE, Herzog MM, Philippon MJ. Performance outcomes in professional hockey players following arthroscopic treatment of FAI and microfracture of the hip. *Knee Surg Sports Traumatol Arthrosc* 2014;22(4):915–9.
8. Singh PJ, O'Donnell JM. The outcome of hip arthroscopy in Australian football league players: a review of 27 hips. *Arthroscopy* 2010;26(6):743–9.

9. Stone AV, Howse EA, Mannava S, et al. Cyclists have greater chondromalacia index than age-matched controls at the time of hip arthroscopy. *Arthroscopy* 2016; 32(10):2102–9.
10. Cameron ML, Briggs KK, Steadman JR. Reproducibility and reliability of the Outerbridge classification for grading chondral lesions of the knee arthroscopically. *Am J Sports Med* 2003;31(1):83–6.
11. Outerbridge RE. The etiology of chondromalacia patellae. *J Bone Joint Surg Br* 1961;43-B:752–7.
12. Beck M, Leunig M, Parvizi J, et al. Anterior femoroacetabular impingement: part II. Midterm results of surgical treatment. *Clin Orthop Relat Res* 2004;(418):67–73.
13. Callaghan JJ, Robenberg AG, Rubash HE. The adult hip. 2nd edition. Philadelphia: Lippincott Williams & Wilkins; 2007.
14. Lynch TS, Steinhaus ME, Popkin CA, et al. Outcomes after diagnostic hip injection. *Arthroscopy* 2016;32(8):1702–11.
15. Migliore A, Granata M, Tormenta S, et al. Hip viscosupplementation under ultrasound guidance reduces NSAID consumption in symptomatic hip osteoarthritis patients in a long follow-up. Data from Italian registry. *Eur Rev Med Pharmacol Sci* 2011;15(1):25–34.
16. Migliore A, Massafra U, Bizzi E, et al. Intra-articular injection of hyaluronic acid (MW 1,500-2,000 kDa; HyalOne) in symptomatic osteoarthritis of the hip: a prospective cohort study. *Arch Orthop Trauma Surg* 2011;131(12):1677–85.
17. Atchia I, Kane D, Reed MR, et al. Efficacy of a single ultrasound-guided injection for the treatment of hip osteoarthritis. *Ann Rheum Dis* 2011;70(1):110–6.
18. Qvistgaard E, Christensen R, Torp-Pedersen S, et al. Intra-articular treatment of hip osteoarthritis: a randomized trial of hyaluronic acid, corticosteroid, and isotonic saline. *Osteoarthr Cartil* 2006;14(2):163–70.
19. Emre TY, Cift H, Seyhan B, et al. Mosaicplasty for the treatment of the osteochondral lesion in the femoral head. *Bull NYU Hosp Jt Dis* 2012;70(4):288–90.
20. Gagala J, Tarczynska M, Gaweda K. Clinical and radiological outcomes of treatment of avascular necrosis of the femoral head using autologous osteochondral transfer (mosaicplasty): preliminary report. *Int Orthop* 2013;37(7):1239–44.
21. Hart R, Janecek M, Visna P, et al. Mosaicplasty for the treatment of femoral head defect after incorrect resorbable screw insertion. *Arthroscopy* 2003;19(10):E1–5.
22. Krych AJ, Lorch DG, Kelly BT. Treatment of focal osteochondral defects of the acetabulum with osteochondral allograft transplantation. *Orthopedics* 2011; 34(7):e307–11.
23. Logan ZS, Redmond JM, Spelsberg SC, et al. Chondral lesions of the hip. *Clin Sports Med* 2016;35(3):361–72.
24. Nam D, Shindle MK, Buly RL, et al. Traumatic osteochondral injury of the femoral head treated by mosaicplasty: a report of two cases. *Hss j* 2010;6(2):228–34.
25. Sotereanos NG, DeMeo PJ, Hughes TB, et al. Autogenous osteochondral transfer in the femoral head after osteonecrosis. *Orthopedics* 2008;31(2):177.
26. Domb BG, Redmond JM, Dunne KF, et al. A matched-pair controlled study of microfracture of the hip with average 2-year follow-up: do full-thickness chondral defects portend an inferior prognosis in hip arthroscopy? *Arthroscopy* 2015; 31(4):628–34.
27. Fickert S, Schattenberg T, Niks M, et al. Feasibility of arthroscopic 3-dimensional, purely autologous chondrocyte transplantation for chondral defects of the hip: a case series. *Arch Orthop Trauma Surg* 2014;134(7):971–8.

28. Fontana A, Bistolfi A, Crova M, et al. Arthroscopic treatment of hip chondral defects: autologous chondrocyte transplantation versus simple debridement—a pilot study. *Arthroscopy* 2012;28(3):322–9.
29. Haviv B, Singh PJ, Takla A, et al. Arthroscopic femoral osteochondroplasty for cam lesions with isolated acetabular chondral damage. *J Bone Joint Surg Br* 2010;92(5):629–33.
30. Karthikeyan S, Roberts S, Griffin D. Microfracture for acetabular chondral defects in patients with femoroacetabular impingement: results at second-look arthroscopic surgery. *Am J Sports Med* 2012;40(12):2725–30.
31. Korsmeier K, Classen T, Kamminga M, et al. Arthroscopic three-dimensional autologous chondrocyte transplantation using spheroids for the treatment of full-thickness cartilage defects of the hip joint. *Knee Surg Sports Traumatol Arthrosc* 2016;24(6):2032–7.
32. MacDonald AE, Bedi A, Horner NS, et al. Indications and outcomes for microfracture as an adjunct to hip arthroscopy for treatment of chondral defects in patients with femoroacetabular impingement: a systematic review. *Arthroscopy* 2016;32(1):190–200.e2.
33. Philippon MJ, Briggs KK, Yen YM, et al. Outcomes following hip arthroscopy for femoroacetabular impingement with associated chondrolabral dysfunction: minimum two-year follow-up. *J Bone Joint Surg Br* 2009;91(1):16–23.
34. Philippon MJ, Schenker ML, Briggs KK, et al. Can microfracture produce repair tissue in acetabular chondral defects? *Arthroscopy* 2008;24(1):46–50.
35. Stafford GH, Bunn JR, Villar RN. Arthroscopic repair of delaminated acetabular articular cartilage using fibrin adhesive. Results at one to three years. *Hip Int* 2011;21(6):744–50.
36. Tzaveas AP, Villar RN. Arthroscopic repair of acetabular chondral delamination with fibrin adhesive. *Hip Int* 2010;20(1):115–9.
37. Domb BG, Gupta A, Dunne KF, et al. Microfracture in the hip: results of a matched-cohort controlled study with 2-year follow-up. *Am J Sports Med* 2015;43(8):1865–74.
38. McGill KC, Bush-Joseph CA, Nho SJ. Hip microfracture: indications, technique, and outcomes. *Cartilage* 2010;1(2):127–36.
39. Cetinkaya S, Toker B, Taser O. Arthroscopic retrograde osteochondral autologous transplantation to chondral lesion in femoral head. *Orthopedics* 2014;37(6):e600–4.
40. Sansone V, de Girolamo L, Pascale W, et al. Long-term results of abrasion arthroplasty for full-thickness cartilage lesions of the medial femoral condyle. *Arthroscopy* 2015;31(3):396–403.
41. Yen YM, Kocher MS. Chondral lesions of the hip: microfracture and chondroplasty. *Sports Med Arthrosc* 2010;18(2):83–9.
42. El Bitar YF, Lindner D, Jackson TJ, et al. Joint-preserving surgical options for management of chondral injuries of the hip. *J Am Acad Orthop Surg* 2014;22(1):46–56.
43. Lodhia P, Gui C, Chandrasekaran S, et al. Microfracture in the hip: a matched-control study with average 3-year follow-up. *J Hip Preservation Surg* 2015;2(4):417–27.
44. Steadman JR, Briggs KK, Rodrigo JJ, et al. Outcomes of microfracture for traumatic chondral defects of the knee: average 11-year follow-up. *Arthroscopy* 2003;19(5):477–84.
45. Steadman JR, Miller BS, Karas SG, et al. The microfracture technique in the treatment of full-thickness chondral lesions of the knee in National Football League players. *J Knee Surg* 2003;16(2):83–6.

46. Haugthorn BD, Erickson BJ, Rybalko D, et al. Arthroscopic acetabular microfracture with the use of flexible drills: a technique guide. *Arthrosc Tech* 2014;3(4):e459–63.
47. Byrd JW, Jones KS. Arthroscopic femoroplasty in the management of cam-type femoroacetabular impingement. *Clin Orthop Relat Res* 2009;467(3):739–46.
48. Chandrasekaran S, Darwish N, Gui C, et al. Outcomes of hip arthroscopy in patients with Tönnis grade-2 osteoarthritis at a mean 2-year follow-up. Evaluation using a matched-pair analysis with Tönnis grade-0 and grade-1 cohorts. *J Bone Joint Surg Am* 2016;98(12):973–82.
49. Bartlett W, Skinner JA, Gooding CR, et al. Autologous chondrocyte implantation versus matrix-induced autologous chondrocyte implantation for osteochondral defects of the knee: a prospective, randomised study. *J Bone Joint Surg Br* 2005;87(5):640–5.
50. Biant LC, Bentley G, Vijayan S, et al. Long-term results of autologous chondrocyte implantation in the knee for chronic chondral and osteochondral defects. *Am J Sports Med* 2014;42(9):2178–83.
51. Gooding CR, Bartlett W, Bentley G, et al. A prospective, randomised study comparing two techniques of autologous chondrocyte implantation for osteochondral defects in the knee: periosteum covered versus type I/III collagen covered. *Knee* 2006;13(3):203–10.
52. Knutsen G, Drogset JO, Engebretsen L, et al. A randomized trial comparing autologous chondrocyte implantation with microfracture. Findings at five years. *J Bone Joint Surg Am* 2007;89(10):2105–12.
53. Mancini D, Fontana A. Five-year results of arthroscopic techniques for the treatment of acetabular chondral lesions in femoroacetabular impingement. *Int Orthop* 2014;38(10):2057–64.
54. Sekiya JK, Martin RL, Lesniak BP. Arthroscopic repair of delaminated acetabular articular cartilage in femoroacetabular impingement. *Orthopedics* 2009;32(9).
55. Cassar-Gheiti AJ, Byrne DP, Kavanagh E, et al. Comparison of four chondral repair techniques in the hip joint: a biomechanical study using a physiological human cadaveric model. *Osteoarthritis Cartil* 2015;23(6):1018–25.
56. Garabekyan TC, Chadayammuri V, Pascual-Garrido C, et al. Arthroscopic bone grafting of deep acetabular cysts using a curved delivery device. *Arthroscopy Tech* 2016;5(1):113–9.
57. Alford JW, Cole BJ. Cartilage restoration, part 2: techniques, outcomes, and future directions. *Am J Sports Med* 2005;33(3):443–60.
58. Beaver RJ, Mahomed M, Backstein D, et al. Fresh osteochondral allografts for post-traumatic defects in the knee. A survivorship analysis. *J Bone Joint Surg Br* 1992;74(1):105–10.
59. Emmerson BC, Gortz S, Jamali AA, et al. Fresh osteochondral allografting in the treatment of osteochondritis dissecans of the femoral condyle. *Am J Sports Med* 2007;35(6):907–14.
60. Meyers MH. Resurfacing of the femoral head with fresh osteochondral allografts. Long-term results. *Clin Orthop Relat Res* 1985;(197):111–4.
61. Evans KN, Providence BC. Case report: fresh-stored osteochondral allograft for treatment of osteochondritis dissecans the femoral head. *Clin Orthop Relat Res* 2010;468(2):613–8.
62. Girard J, Roumazielle T, Sakr M, et al. Osteochondral mosaicplasty of the femoral head. *Hip Int* 2011;21(5):542–8.